

# The Cardiovascular System

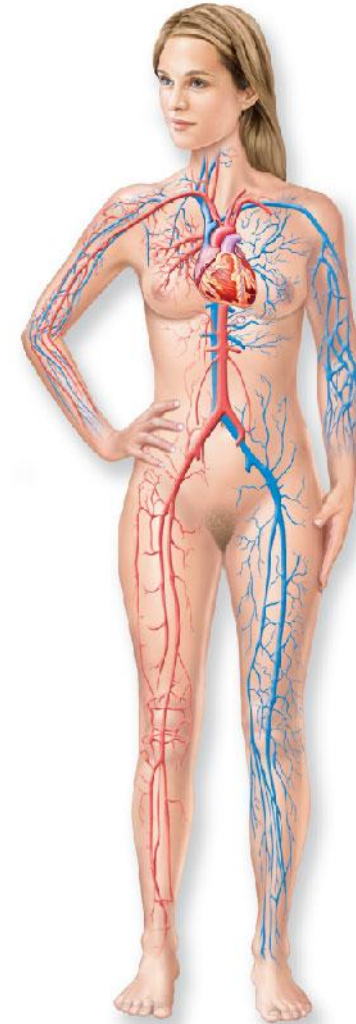Using your medical terminology word roots, what does cardiovascular mean?



Students, write your response!

# The Cardiovascular System

- Structures
  - A closed system of the **heart (cardio-)** and **blood vessels (vas-)**
    - The heart **pumps blood**
    - Blood vessels **allow blood to circulate to all parts of the body**



# The Cardiovascular System

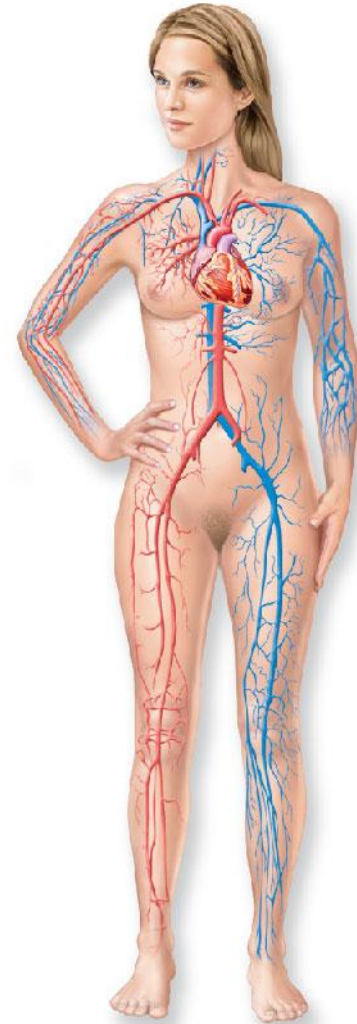What are the functions of the cardiovascular system?



Students, write your response!

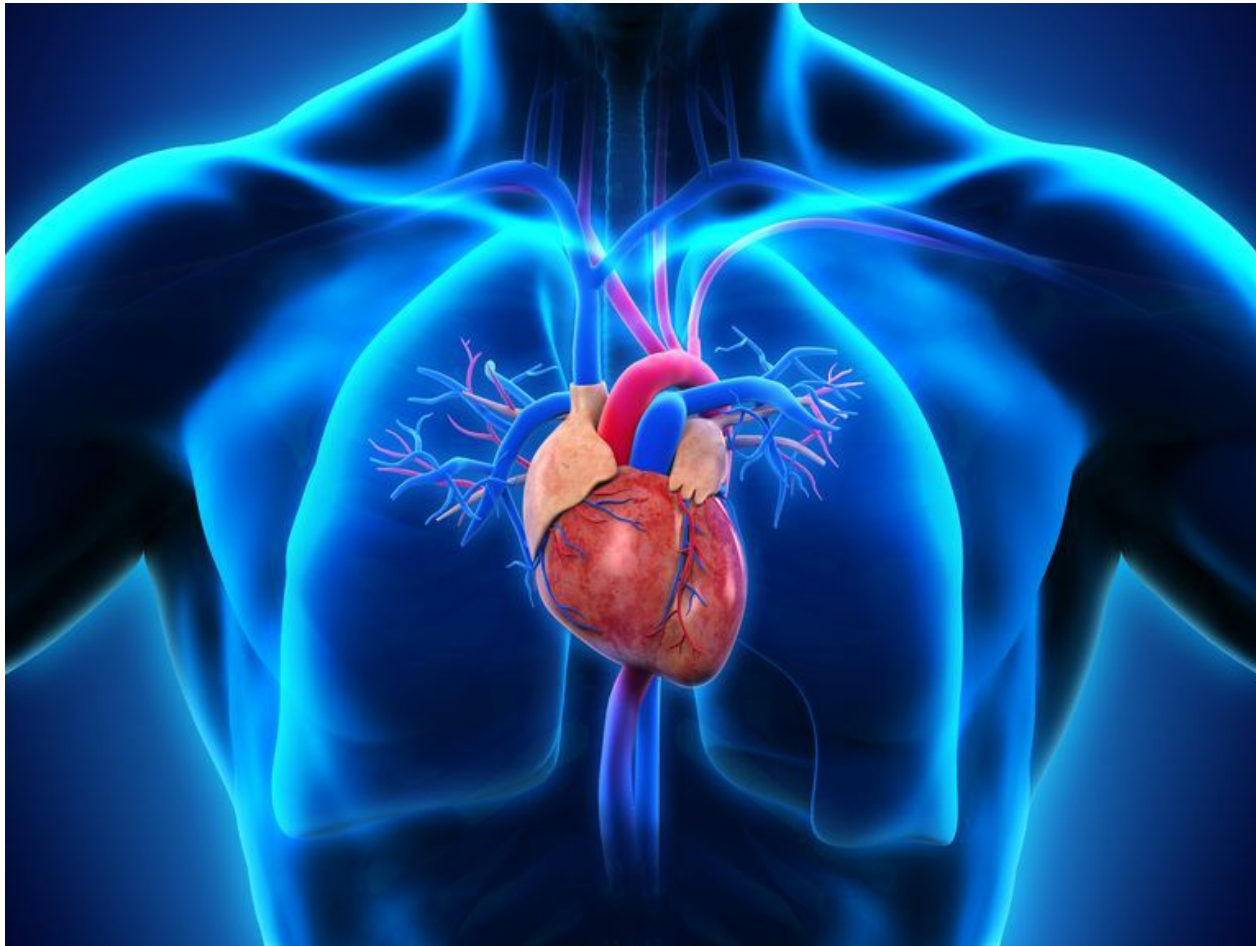# The Cardiovascular System

- Functions
  - **Transport oxygen, nutrients, cell wastes, hormones to and from cells**



# Anatomy of the Heart

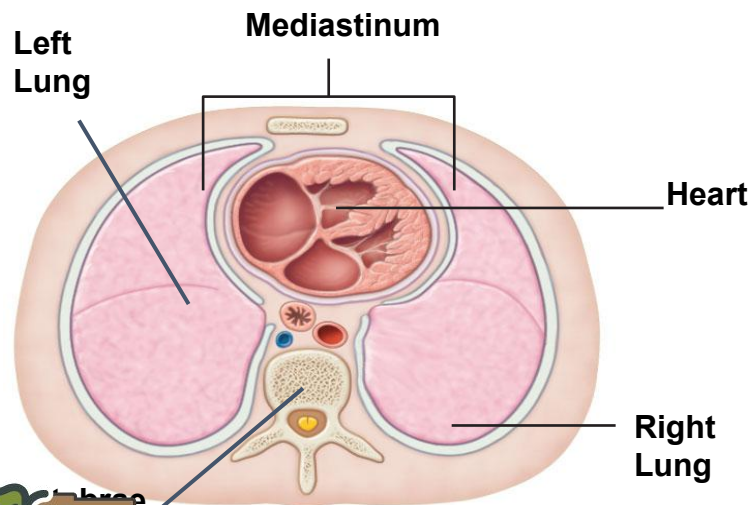
- **Hollow, cone-shaped, muscular pump**
  - Size of a human fist, weighing less than a pound



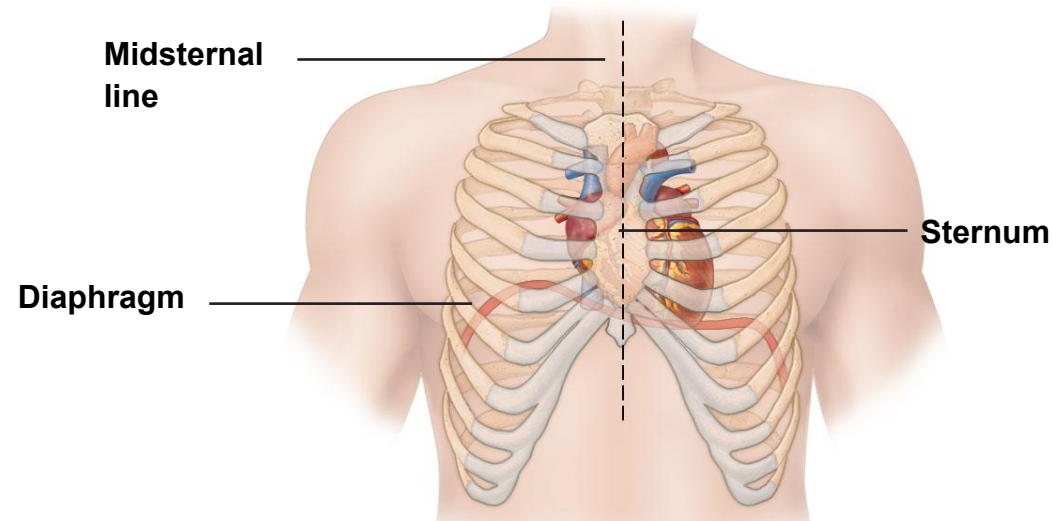
# Anatomy of the Heart

- Location

- In the **inferior mediastinum** of the thoracic cavity
- Bordered \_\_\_\_\_ by the lungs, \_\_\_\_\_ by the vertebral column, \_\_\_\_\_ by the sternum, and \_\_\_\_\_ by the diaphragm



**Posterior View**



**Anterior View**

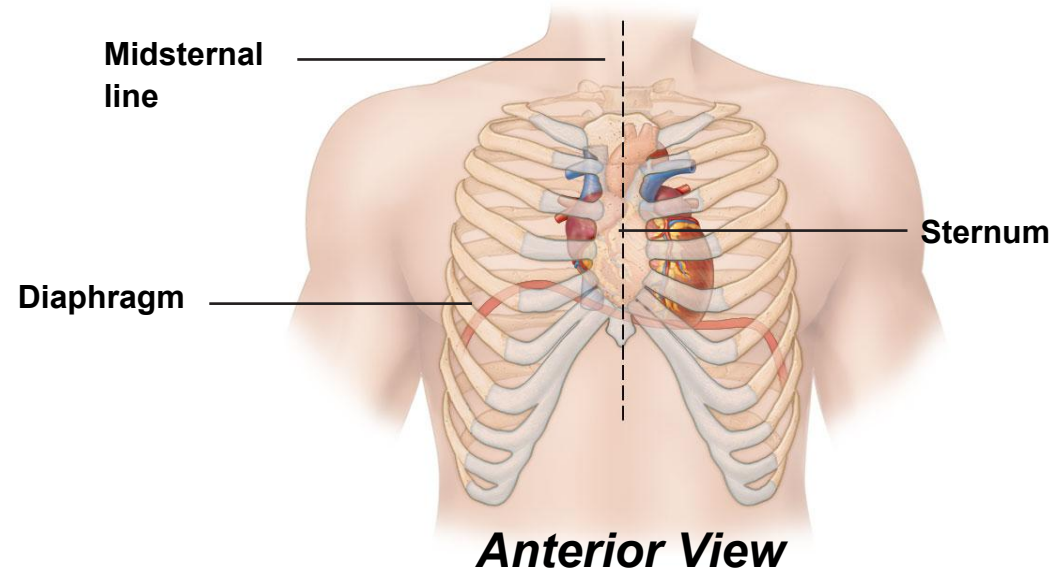
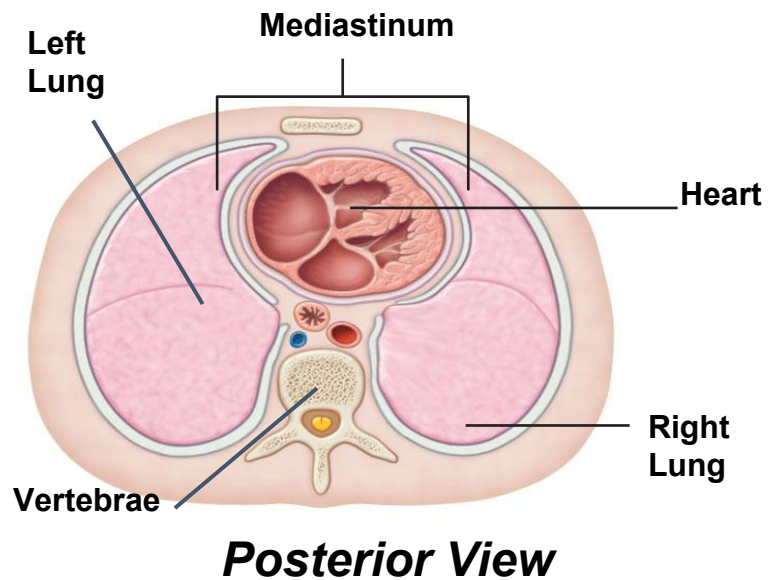
Students, draw anywhere on this slide!

Real Deck Interactive Slide  
Do not remove this bar

# Anatomy of the Heart

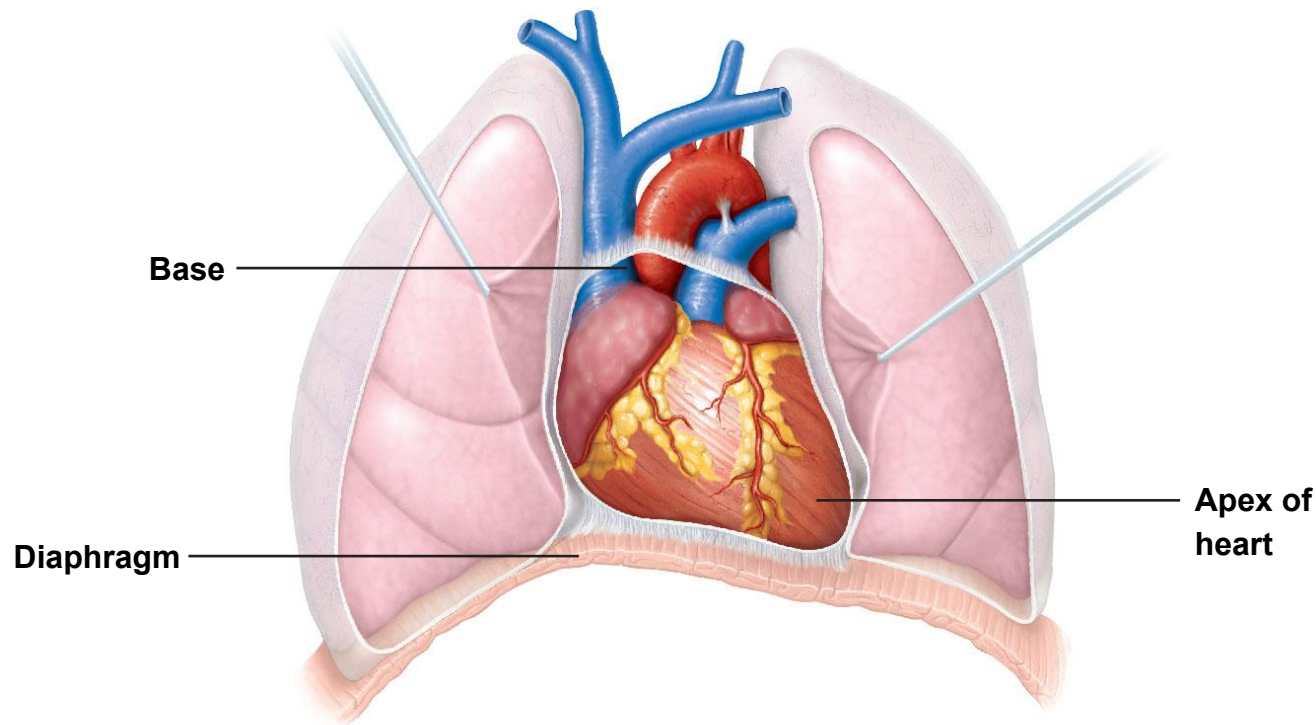
## ■ Location

- In the **inferior mediastinum** of the thoracic cavity
- Bordered **laterally** by the lungs, **posteriorly** by the vertebral column, **anteriorly** by the sternum, and **inferiorly** by the diaphragm



# Anatomy of the Heart

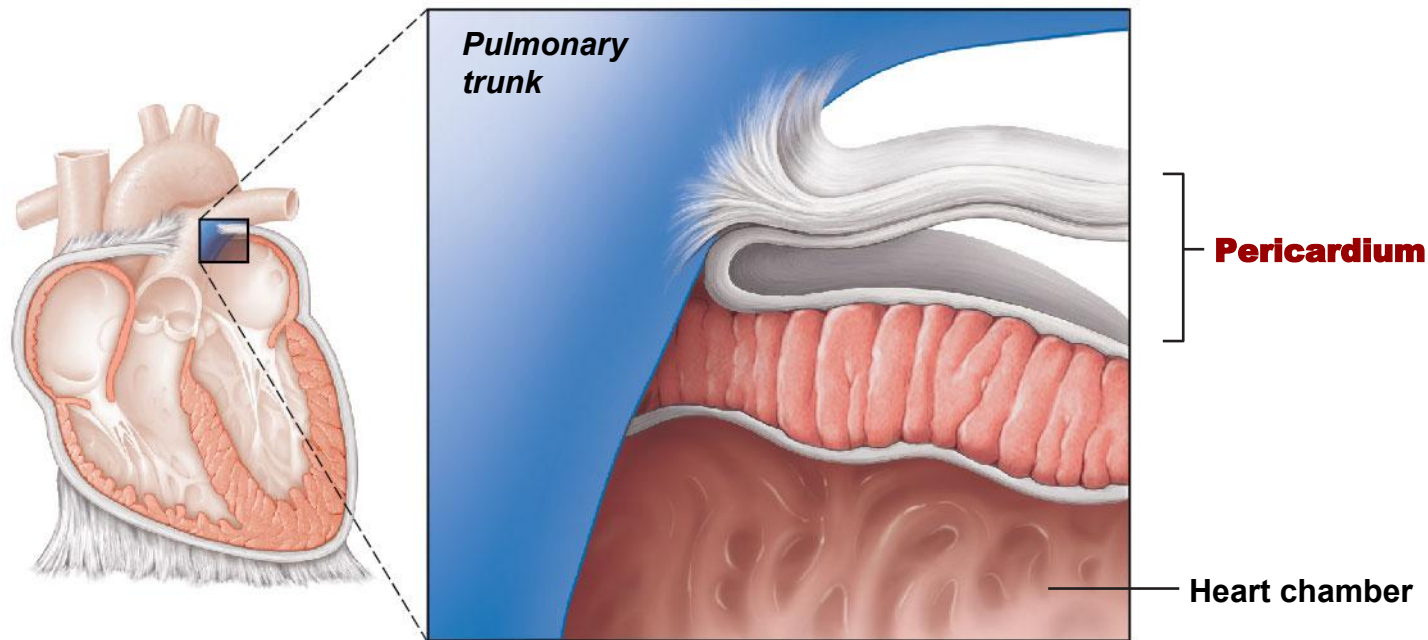
- Orientation
  - **Apex** (tip) is directed toward the **left hip** and rests on the **diaphragm**
  - **Base** points toward the **right shoulder**





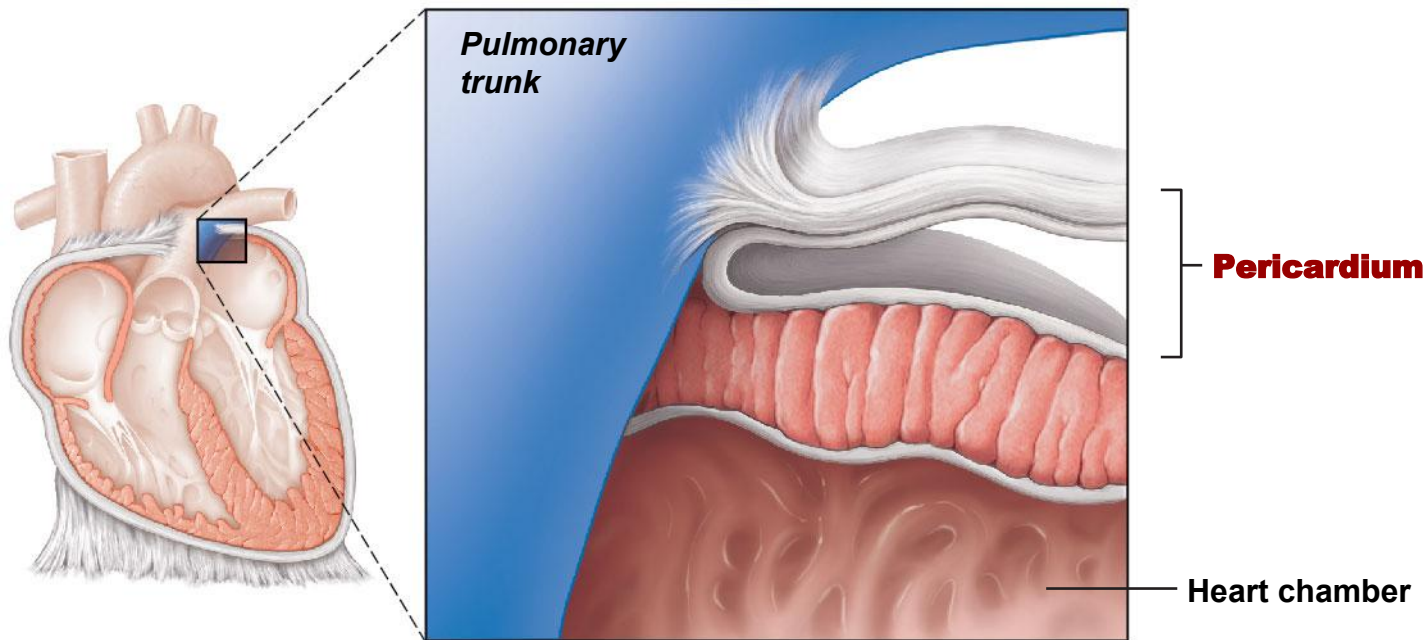
# Anatomy of the Heart

- Coverings of the heart
  - **Pericardium** - a double-walled sac enclosing the heart
    1. **Fibrous pericardium**
    2. **Serous pericardium**

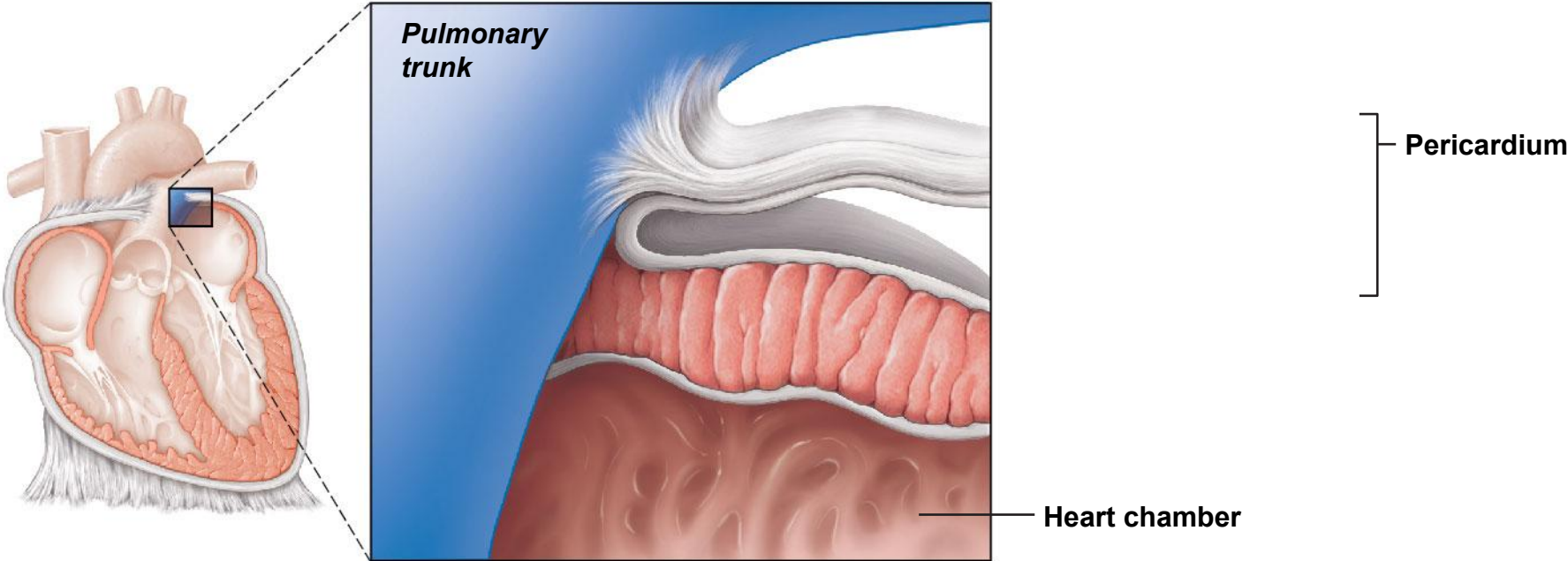


# Anatomy of the Heart

- Coverings of the heart
  - **Fibrous pericardium**
    - ✓ Outer (**superficial**), tough layer made of **dense connective tissue**

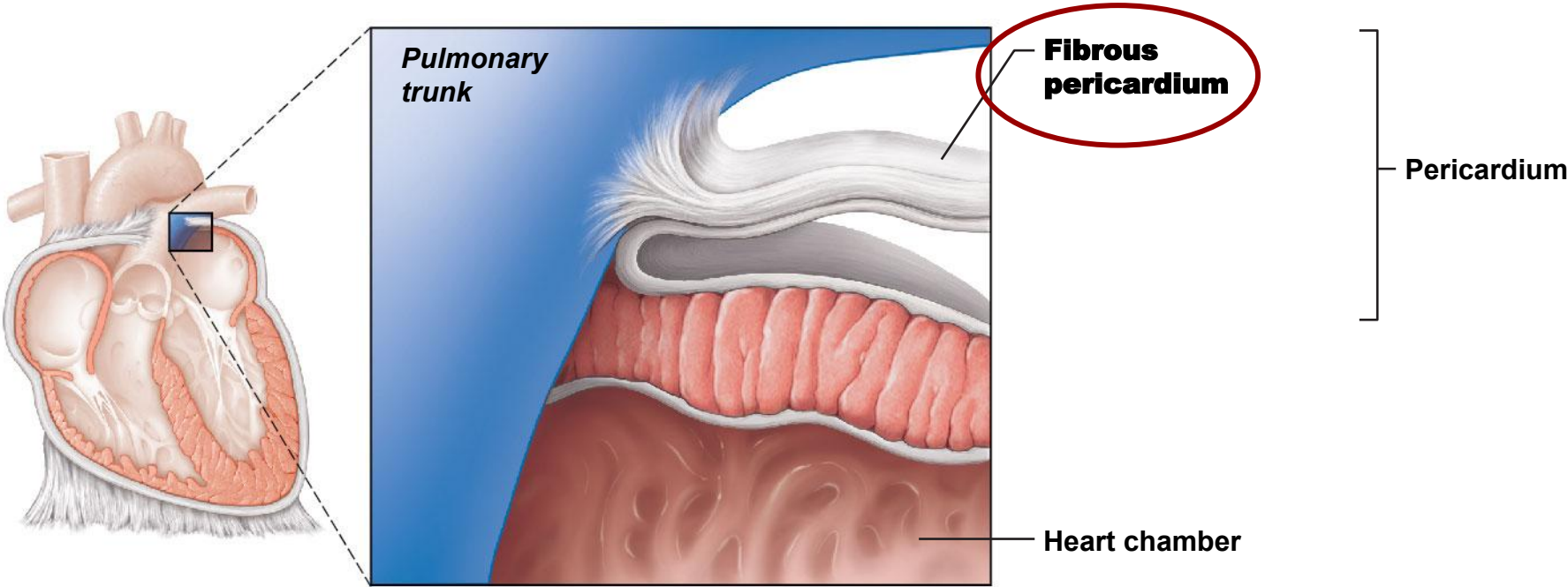


# Label the fibrous pericardium



Students, draw anywhere on this slide!

# Fibrous pericardium



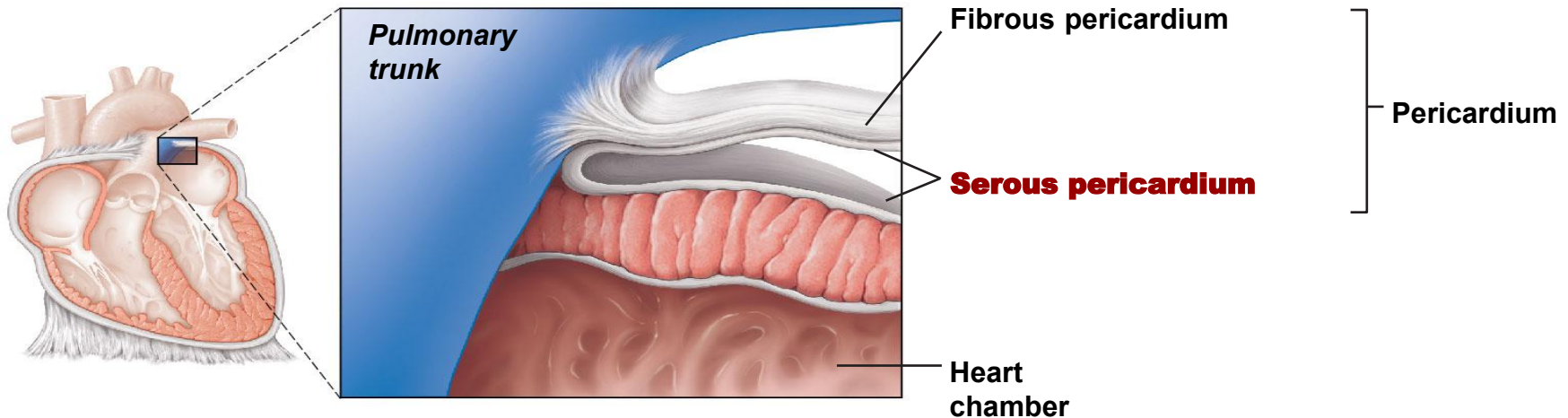
# Anatomy of the Heart

- Coverings of the heart

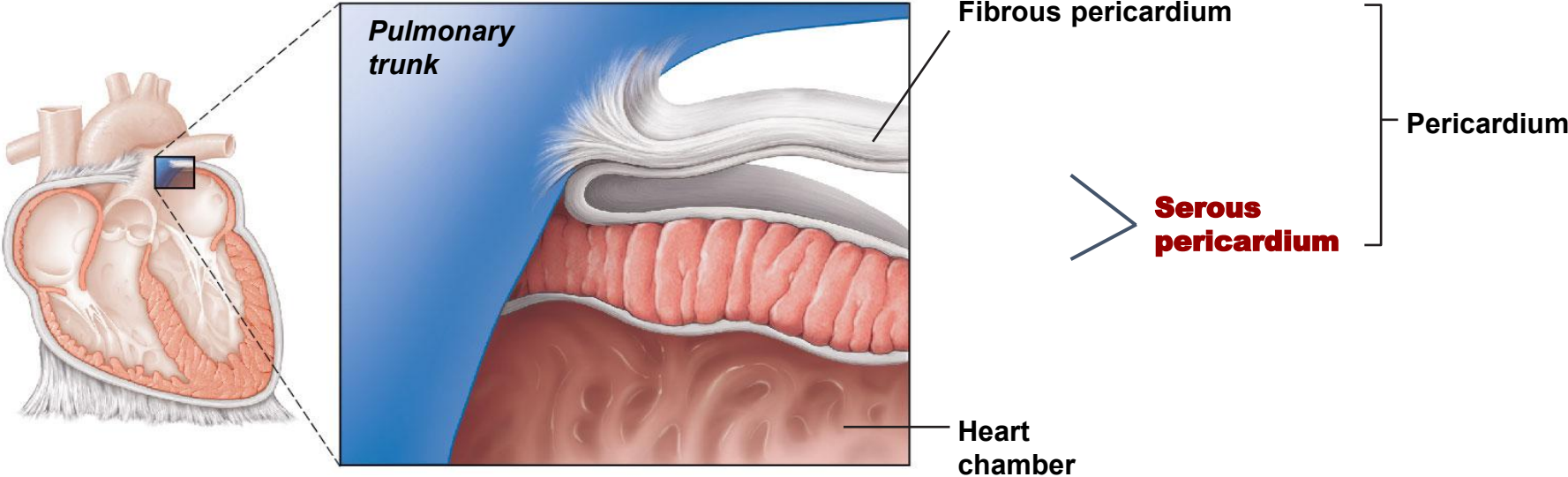
- **Serous pericardium**

- ✓ **Deep** to the fibrous pericardium and composed of two **connective tissue** layers:

1. **Parietal pericardium**: outside layer that lines the inner surface of the fibrous pericardium
2. **Visceral pericardium**: next to heart; also known as the *epicardium*

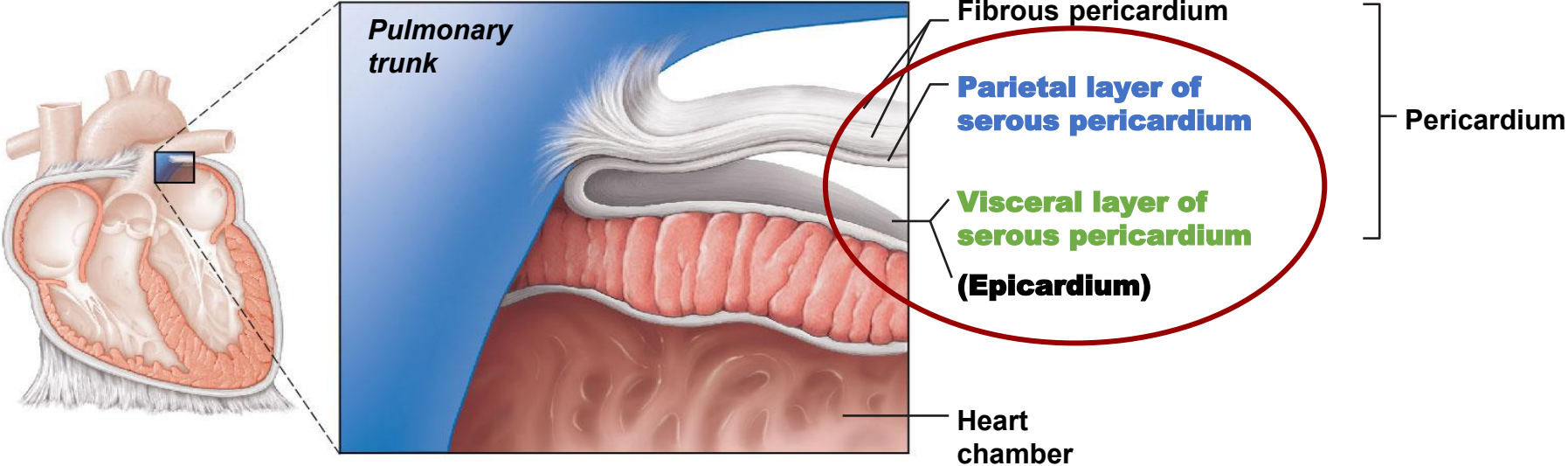


# Label the parietal and visceral layer of serous pericardium



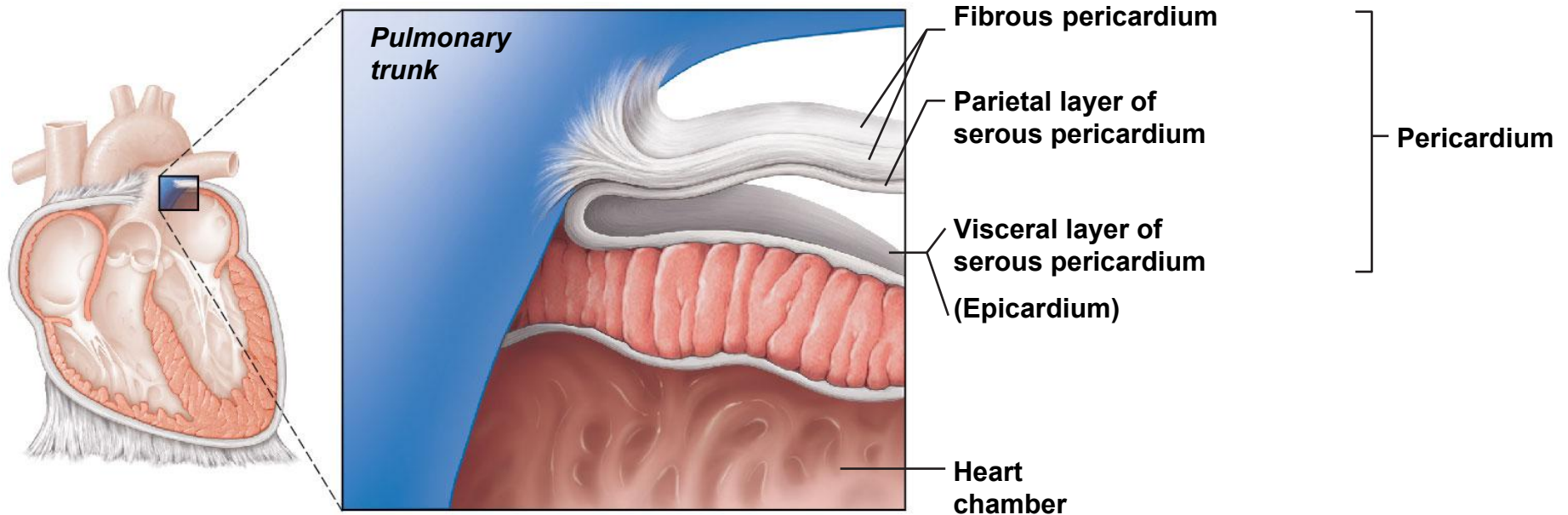
Students, draw anywhere on this slide!

# Parietal and Visceral layers of serous pericardium



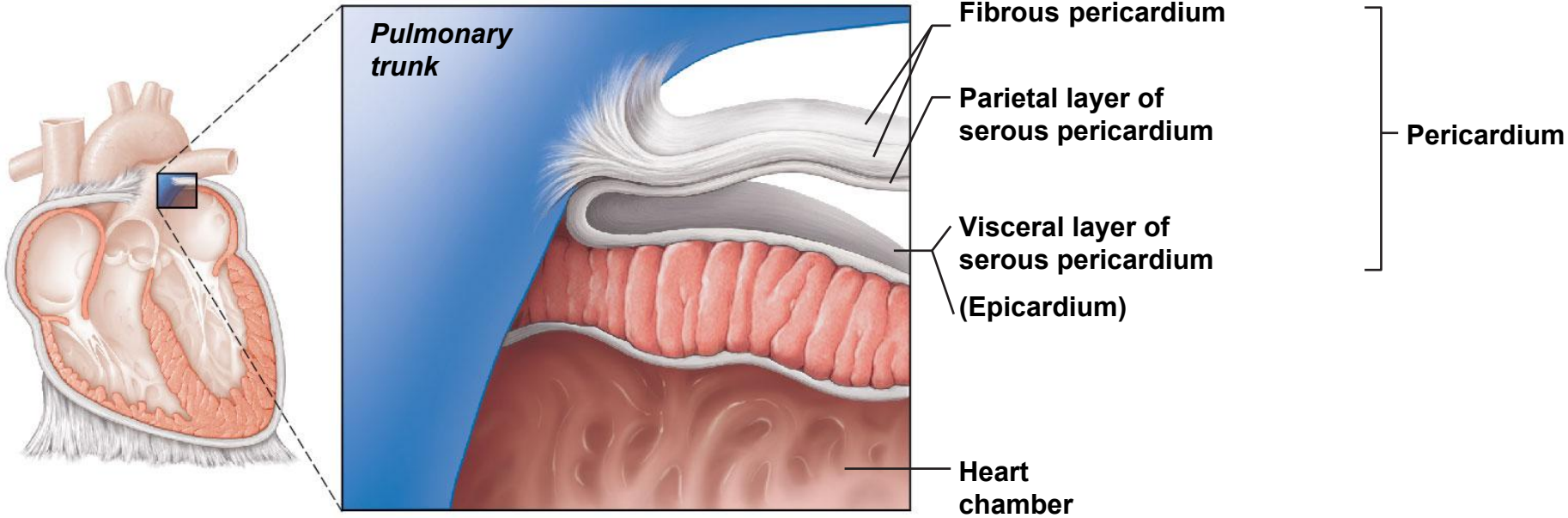
# Anatomy of the Heart

- Coverings of the heart
  - **Pericardial cavity** - space between the layers of pericardium filled with **serous fluid**
    - ✓ **Reduces friction** as the heart pumps



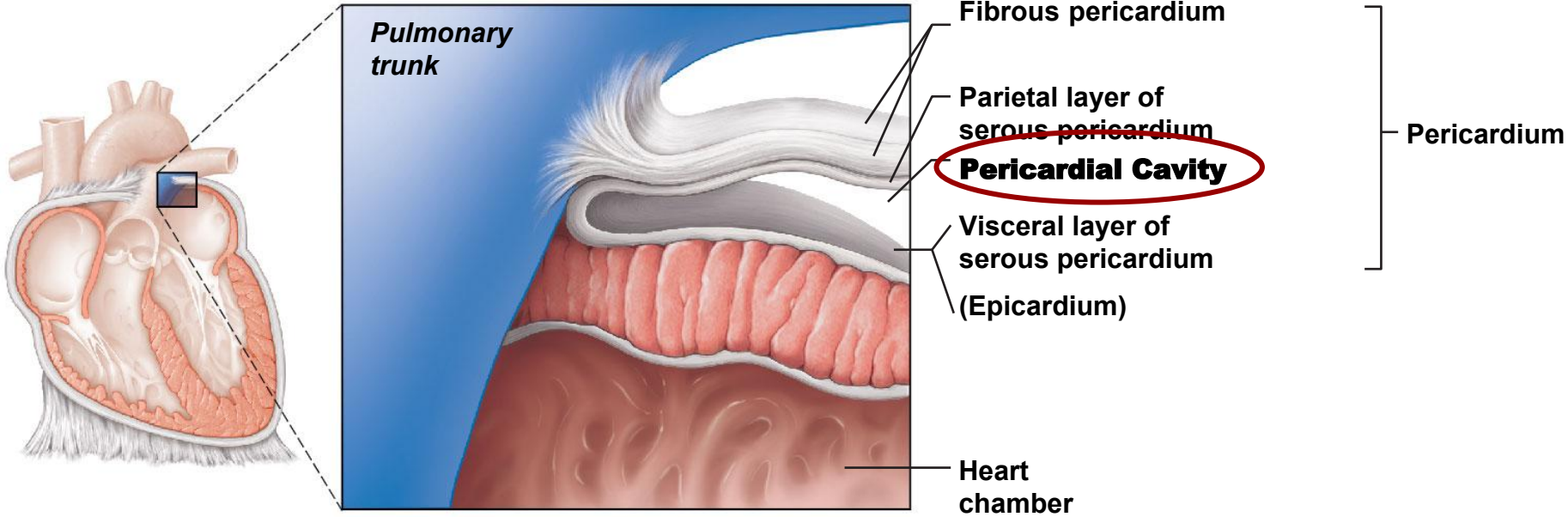


# Label the Pericardial Cavity



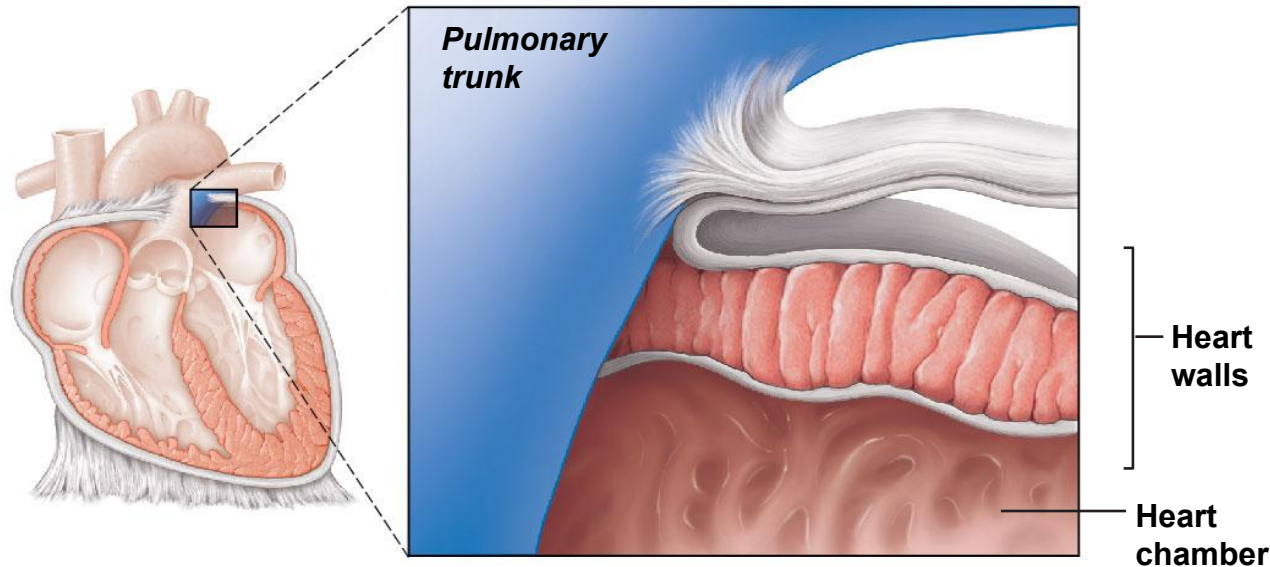
Students, draw anywhere on this slide!

# Pericardial Cavity

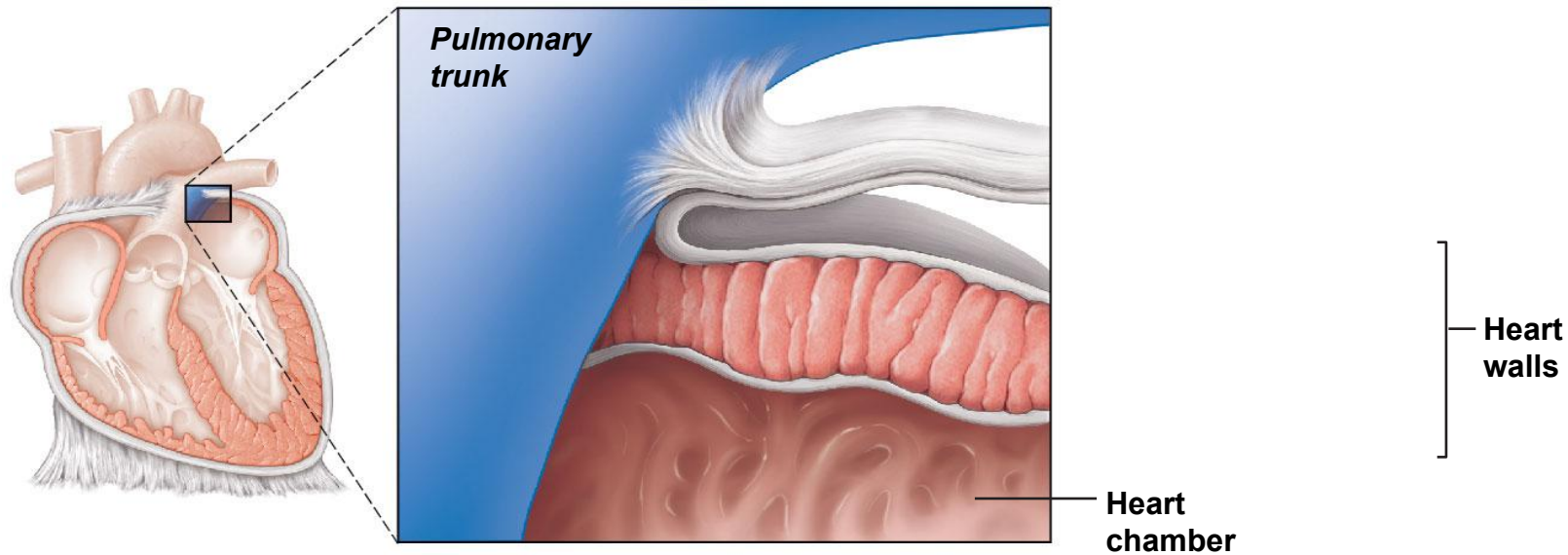


# Anatomy of the Heart

- Walls of the heart
  - 1. Epicardium (visceral pericardium)**
    - Outside layer
  - 2. Myocardium**
    - Middle layer
  - 3. Endocardium**
    - Inner layer

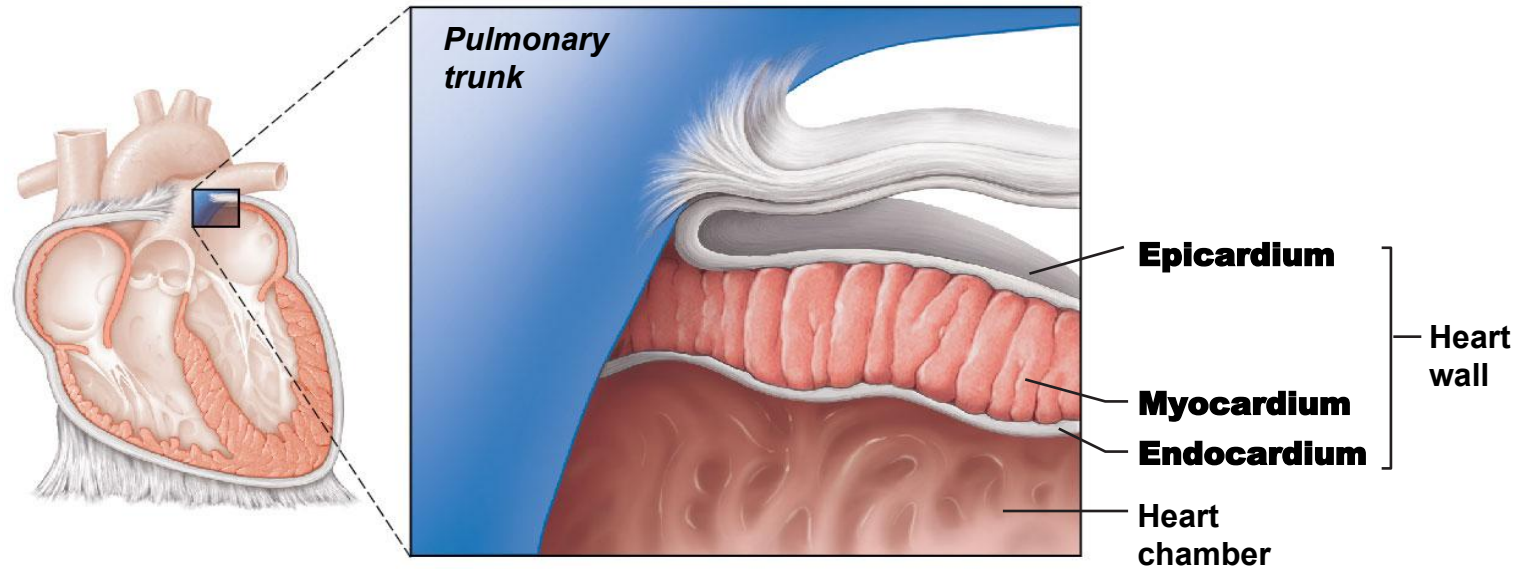


# Label the walls of the heart: epicardium, myocardium, and endocardium



Students, draw anywhere on this slide!

# Walls of the heart

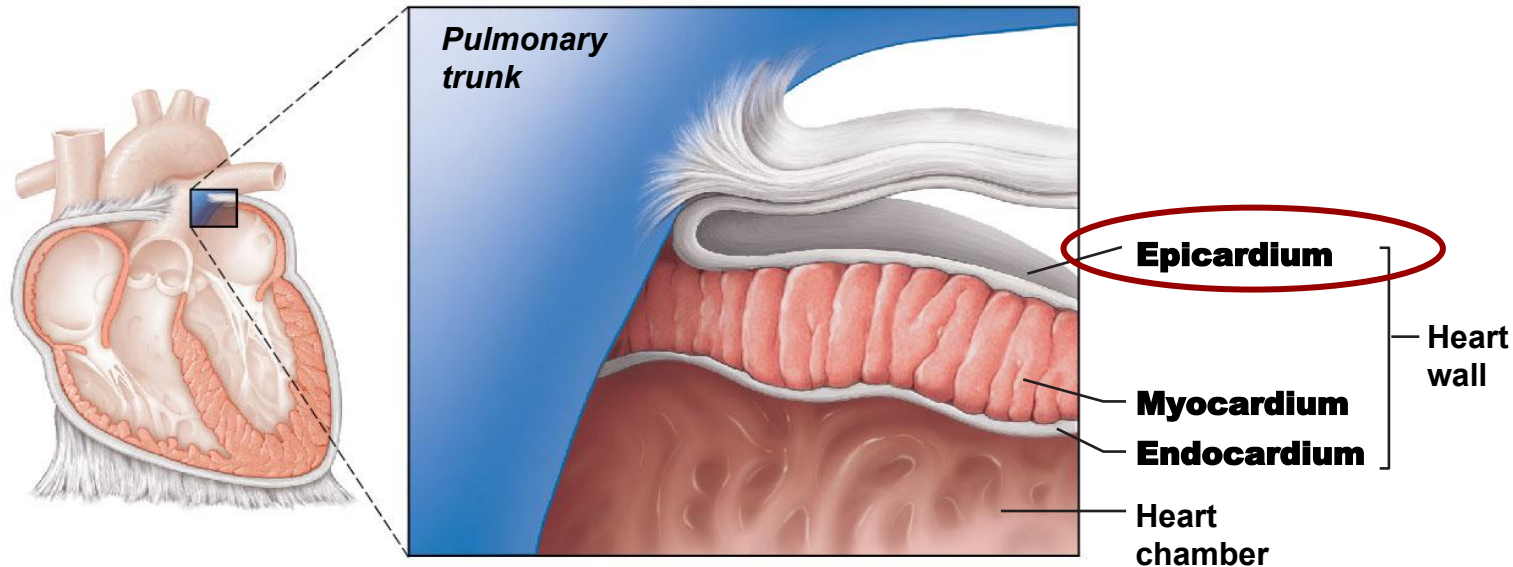


# Anatomy of the Heart

- Walls of the heart

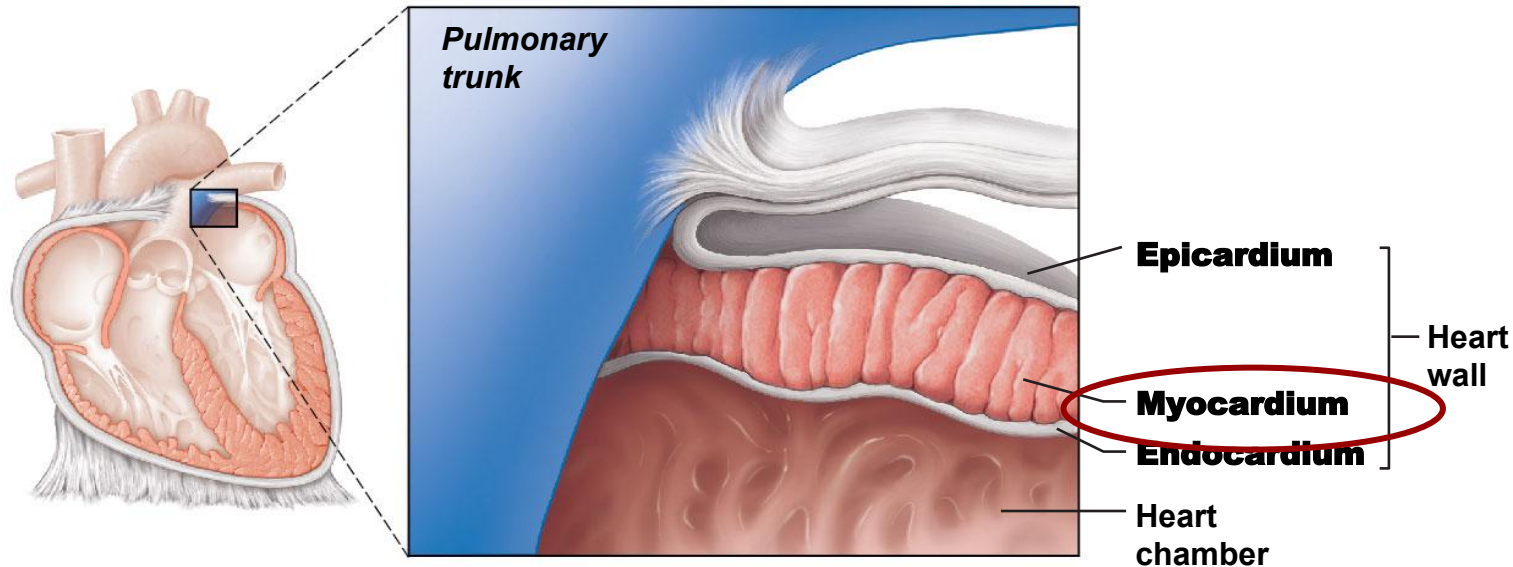
- Epicardium**

- Serous membrane of connective tissue covered with epithelium
- Forms a protective outer covering**
- Secretes serous fluid**



# Anatomy of the Heart

- Walls of the heart
  2. **Myocardium**
    - **Cardiac muscle tissue**
    - **Contracts to pump blood** from the heart chambers

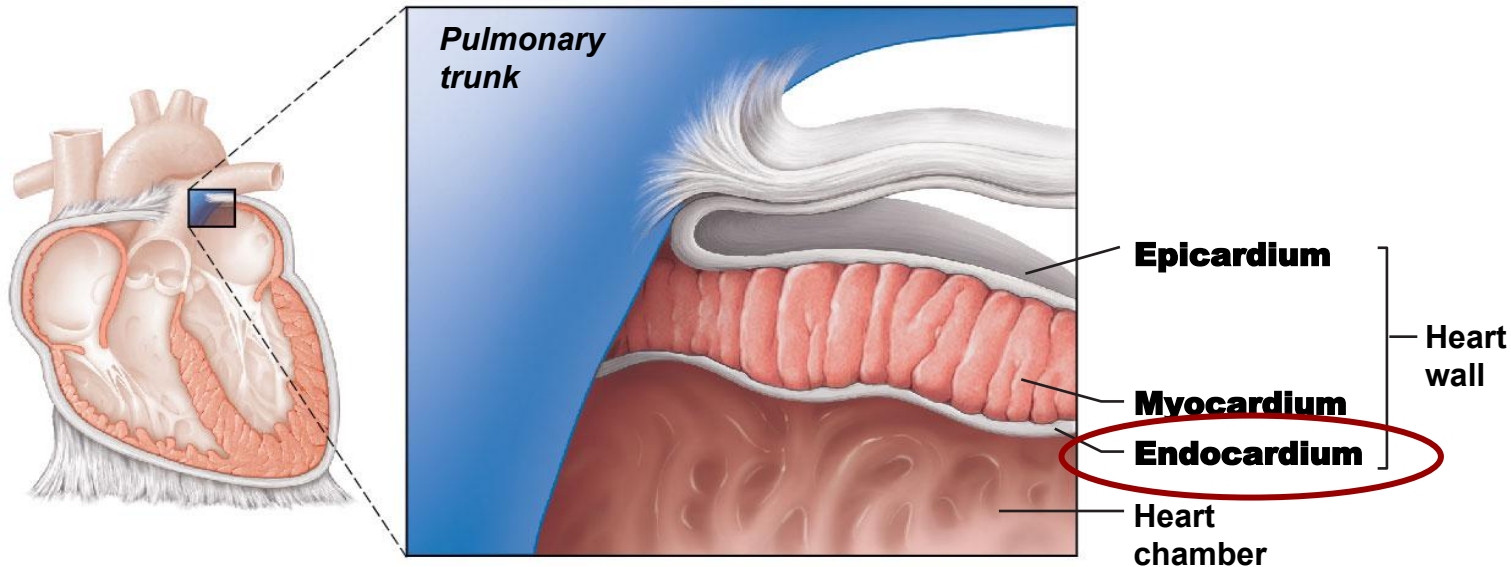


# Anatomy of the Heart

- Walls of the heart

- 3. Endocardium**

- Membrane of **epithelial tissue**
    - Forms a protective inner lining** of the chambers and valves

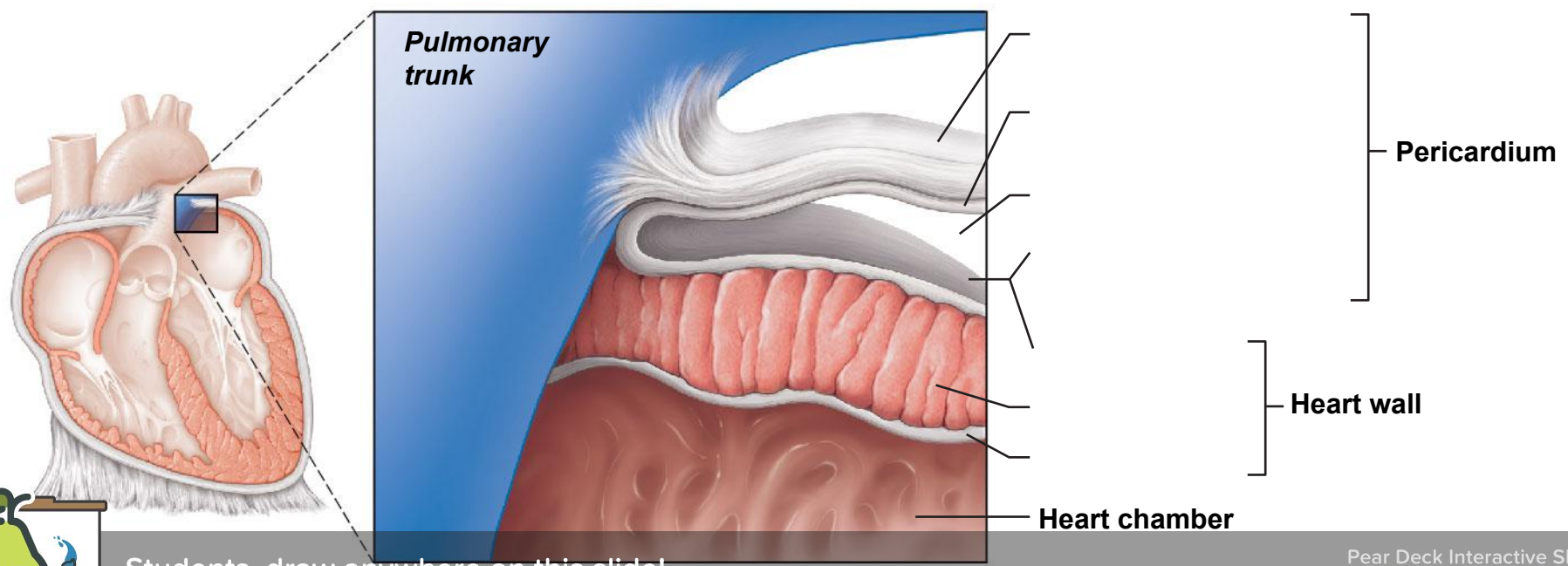




# Put it ALL together. Label the coverings and walls of the heart

Fibrous pericardium  
Parietal layer of serous pericardium  
Visceral layer of serous pericardium  
Pericardial cavity

Epicardium  
Myocardium  
Endocardium



Students, draw anywhere on this slide!

# Put it ALL together. Label the coverings and walls of the heart

Fibrous pericardium  
Parietal layer of serous pericardium  
Visceral layer of serous pericardium  
Pericardial cavity

Epicardium  
Myocardium  
Endocardium

